

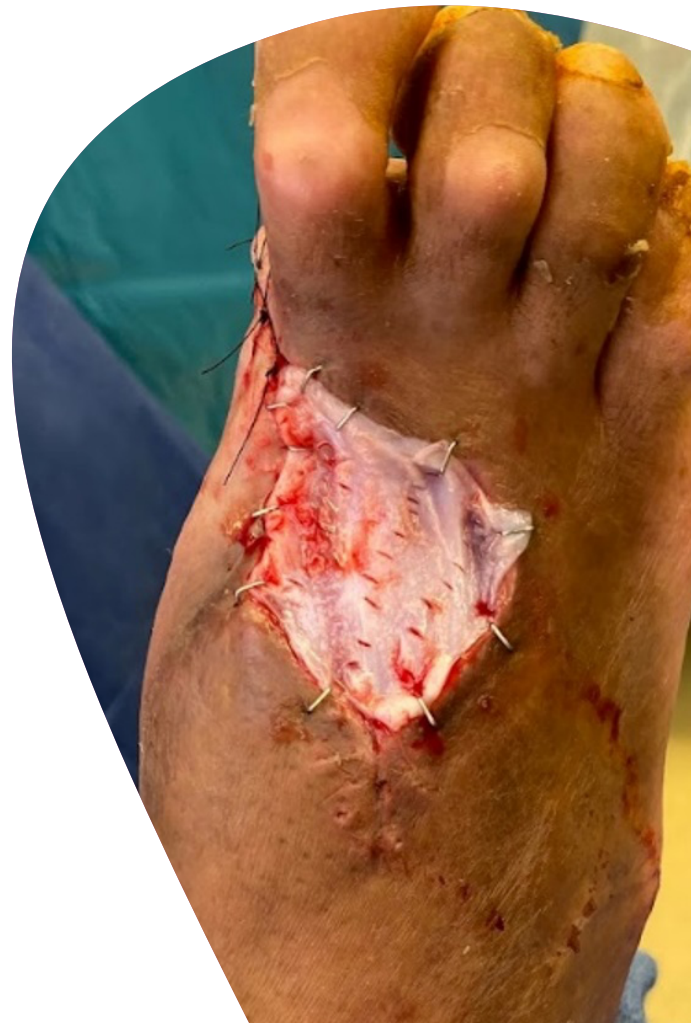+ Limb Salvage Surgery

Get your patients back to their lives. Faster.

Smith+Nephew

STRAVIX PL[◇]
Lyopreserved
Umbilical Tissue

STRAVIX[◇]
Cryopreserved
Umbilical Tissue



Improve outcomes faster and conveniently

Ideal for limb salvage procedures

A single STRAVIX[◇] Tissue can provide fast closure for soft tissue defects and complex wounds.¹

In a retrospective, single-center study on the surgical management of large soft tissue defects in patients with gas gangrene, all patients achieved complete wound closure following a single STRAVIX Tissue application.¹

13.4 weeks
for wound
closure (mean)

9 days hospital stay (mean) vs.
31.1 days hospital stay (mean)
in a database review of **11,666**
patients with gas gangrene in
the foot²

68.4% percent
area reduction at 4
weeks (mean)

Minimal scarring

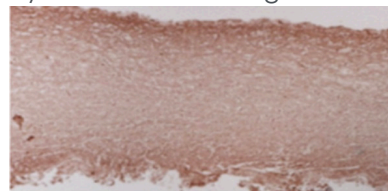
Restoration of natural pigmentation

Manufactured using proprietary processes allowing the structural tissues to retain all native components^{3,4}


- Extracellular matrix rich in hyaluronic acid^{3,4}
- Growth factors such as bFGF, VEGF, and IL-10^{3,4}

Key protein remains intact^{3,4}

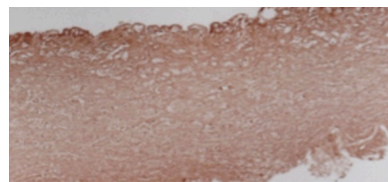
Hyaluronic acid staining



Fresh umbilical tissue



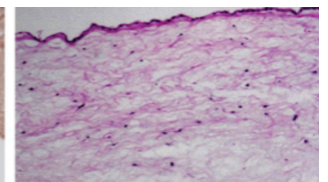
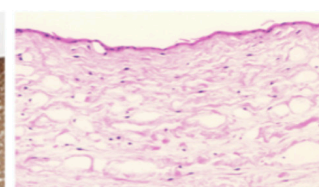
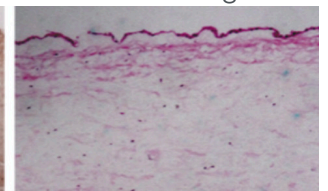
STRAVIX Tissue



STRAVIX PL[◇] Tissue

3D matrix remains intact^{3,4}

H&E tissue staining




STRAVIX[◇] Tissues for wounds small or large



Choose STRAVIX PL[◇] Tissue for off-the-shelf, on-demand convenience

No thawing or special refrigeration required



Choose STRAVIX Meshed Tissue for larger wounds

A more affordable choice that is easily stretched to cover larger areas

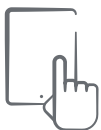The STRAVIX Tissue portfolio is durable, strong and versatile

1 to 3 millimeters thick

Intimately adapts to injured tissue to form adhesion barrier

High tensile strength:
Stronger than amnion alone⁴

Easy to maneuver, suture and apply including with arthroscopic and robotic procedures



Learn more
stravixpl.com



Add the convenience of STRAVIX PL and STRAVIX Meshed Tissues to your surgical protocols for fast effective results without adding significant costs^{1-2, 5-6}

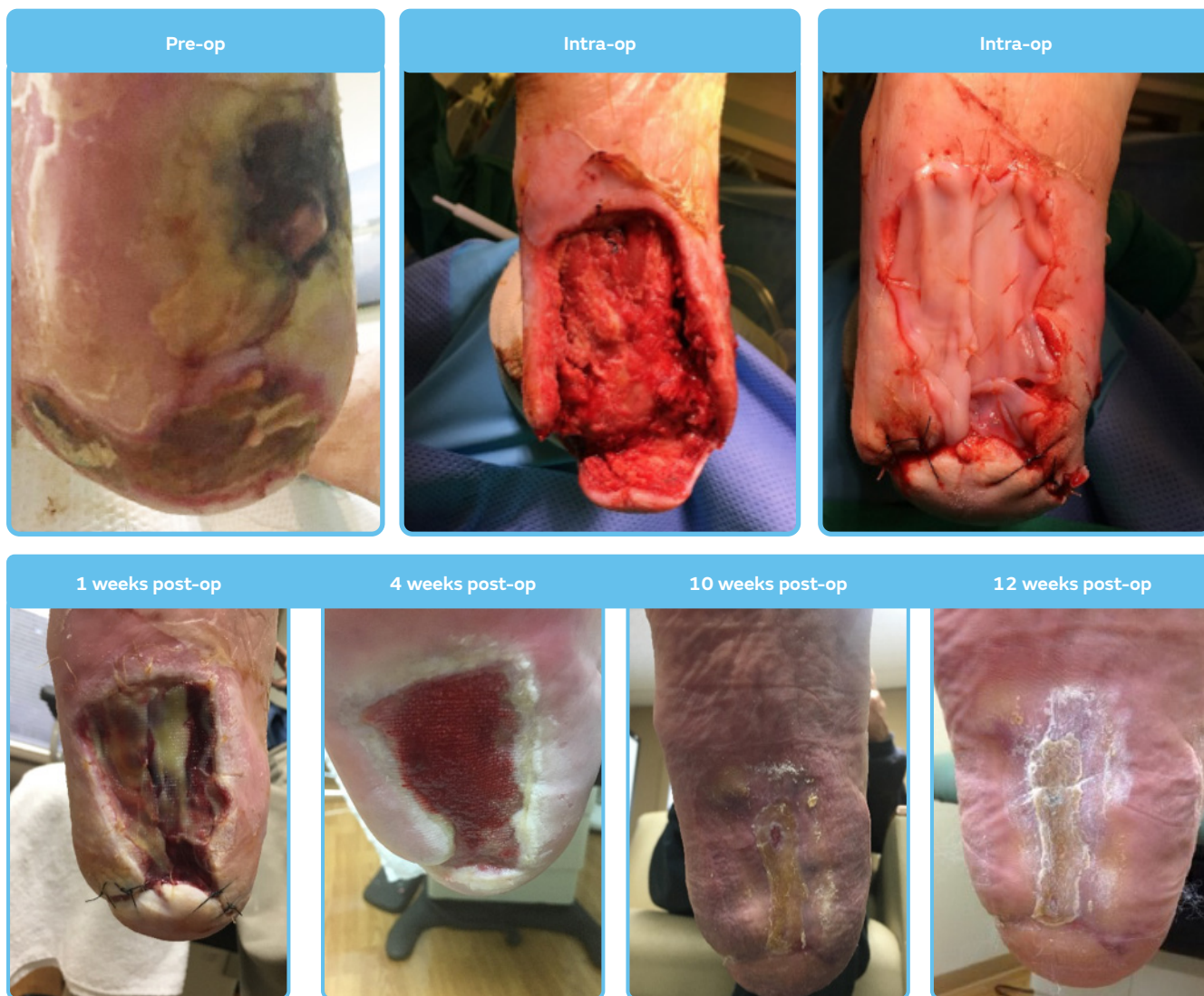
STRAVIX^o Tissue case study: complex wound¹

Patient and diagnosis

- 76-year-old male
- History of type II diabetes, coronary artery disease, hypertension, and peripheral artery disease
- Presented with an infected right heel

Wound treatment/procedure

- Immediate I&D and a partial right calcaneotomy were performed after all of the necrotic and infected tissue was debrided
- NPWT was applied intermittently for 4 days at 125 mm Hg during hospitalization
- Fenestrated STRAVIX Tissue was placed into the wound bed and sutured to the edges



Outcome

- The patient was discharged from the hospital on day 12
- At 4 weeks, percent area reduction was 52%
- Wound closed by 12 weeks post-op

STRAVIX PL^o Tissue case study: gas gangrene

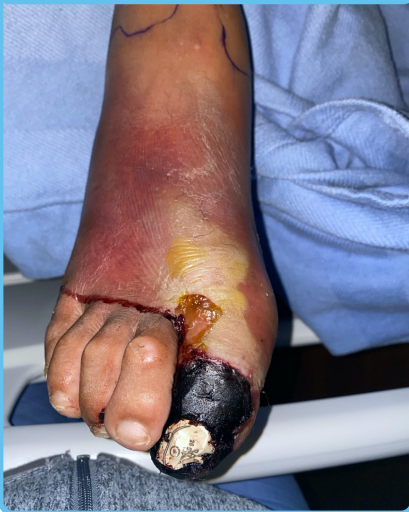Patient and diagnosis

- 61-year-old homeless male with gas gangrene with a surgical deficit after partial 1st ray amputation
- Type II diabetes with HbA1c of 11.5%
- Presented with worsening foot pain and necrotic hallux
 - WBC – 19.2
 - ESR – 94
 - CRP – >200.0

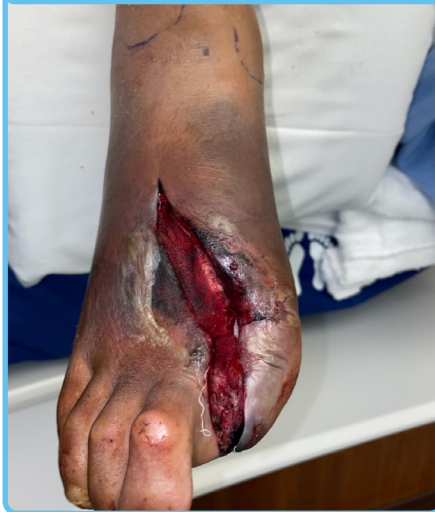Wound treatment/procedure

- Initial open partial 1st ray amputation, repeat debridement, and final debridement with one STRAVIX PL Tissue application and NPWT application
- STRAVIX PL Tissue was placed because of the depth of the surgical defect and exposed structures
- NPWT d/c after 1 week
- Complete closure at 8 weeks

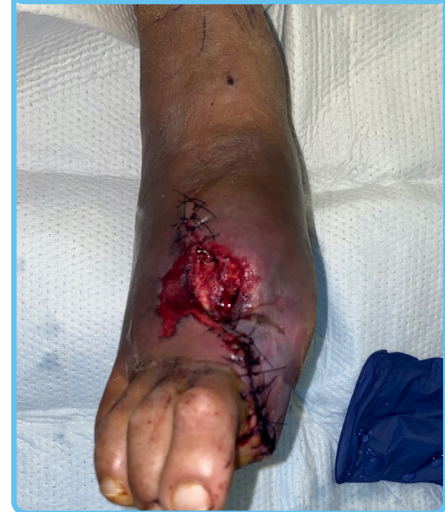Initial presentation



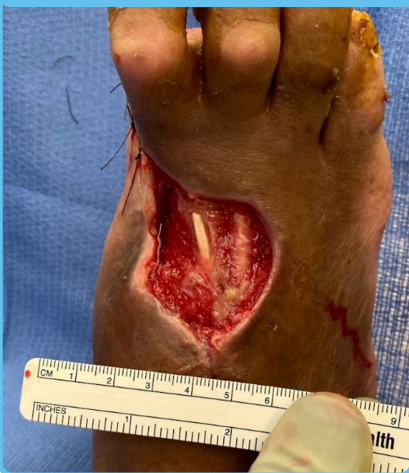Initial debridement



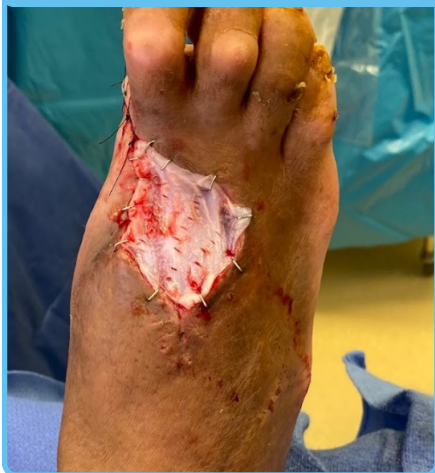Initial closure



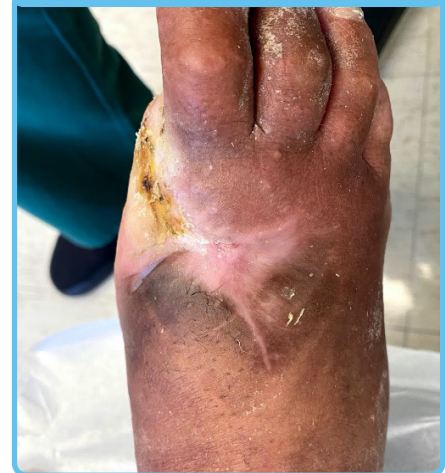Pre-STRAVIX PL Tissue application
7.2 cm x 4.2 cm x 0.3 cm



STRAVIX PL Tissue Application



Complete closure in 8 weeks



Outcome

- NPWT x 1 week
- Antibiotics x 2 weeks
- STRAVIX PL Tissue completely metabolized in 3.5 weeks
- Complete wound closure in 8 weeks
- Functional ambulatory foot

STRAVIX PL^o Tissue Case study: Diabetic foot infection

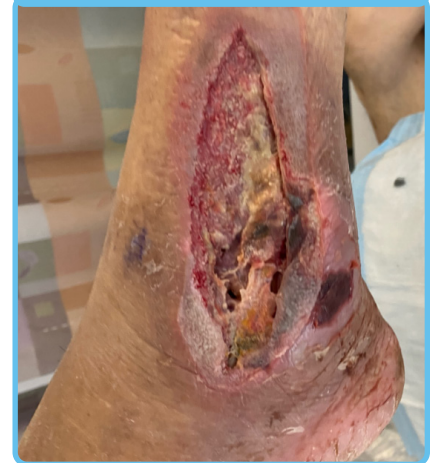Patient and diagnosis

- 51-year-old male
- No past medical history, A1C 9.4%
- Twisted ankle 1 week prior
- X-ray and CT showed gas plantar, medial and lateral
- Diagnosis – Large open wounds
- Lateral wound mostly fibrotic with exposed peroneal tendons
- Lateral wound measurement – 12 cm x 6 cm

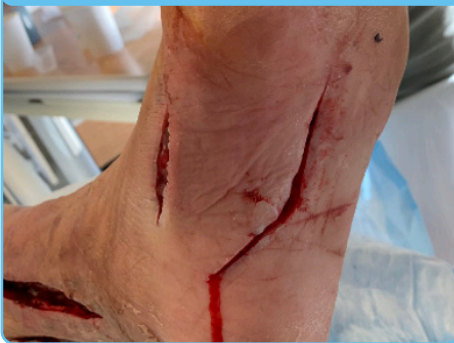Wound treatment/procedure

- I&D x 2, debridement x 1
- Applied external fixator and STRAVIX PL Tissue
- 6 weeks Cefazolin antibiotic

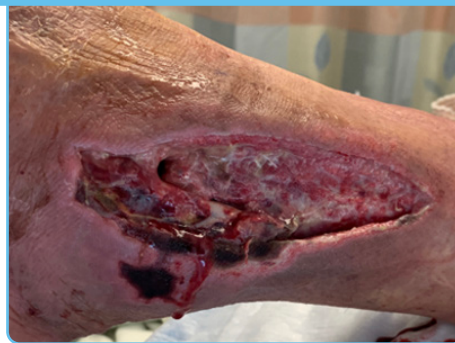Initial presentation



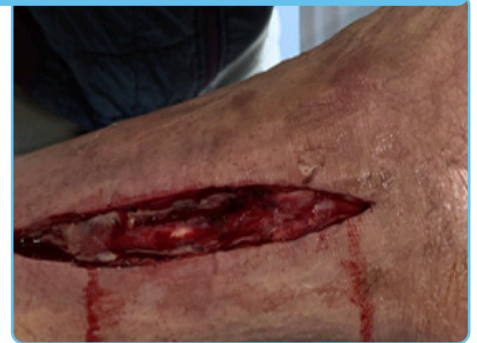Plantar incisions



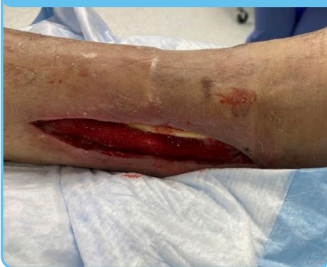Lateral wound



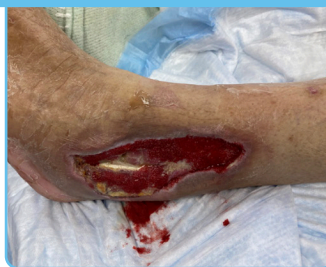Medial wound



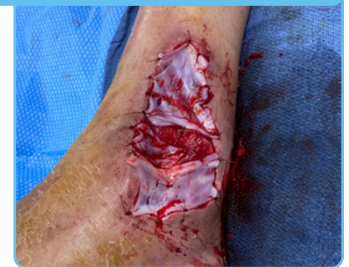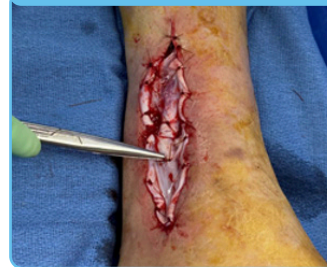Medial 13 cm x 2.5 cm



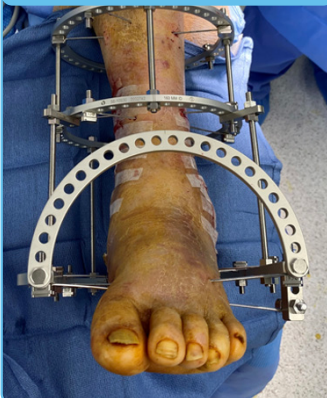Lateral 13 cm x 6 cm



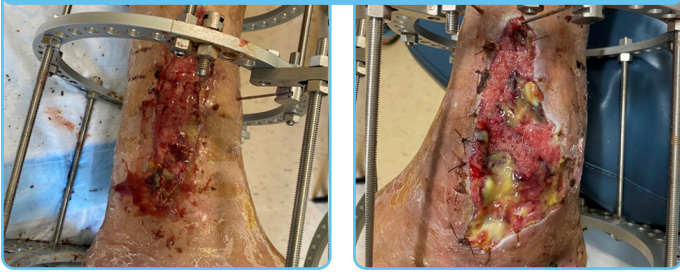
Intraoperative: Application of STRAVIX PL Tissue in the OR



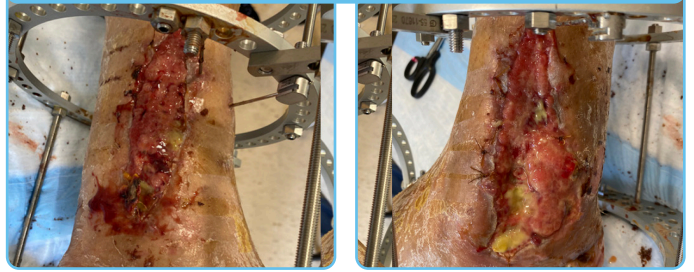
External fixator applied
debridement



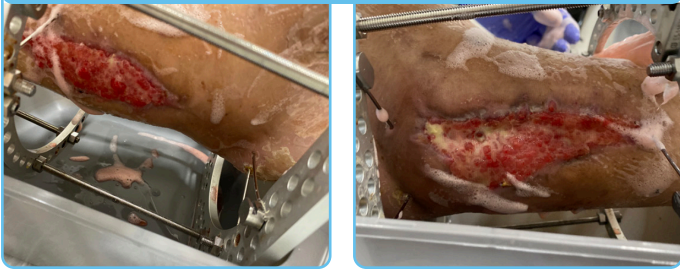Two weeks post op: : improvement in depth of wounds



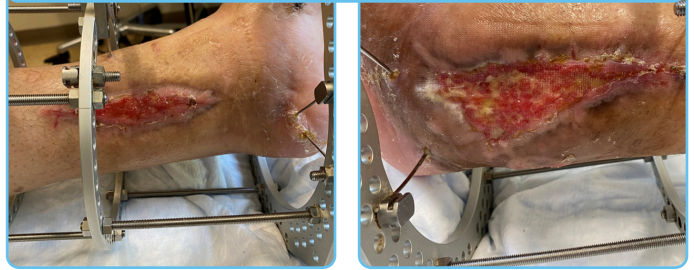
Four weeks post op: ankle joint almost completely covered



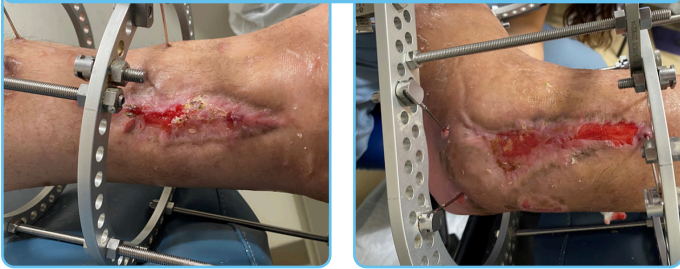Six weeks post op: healthy granulation tissue



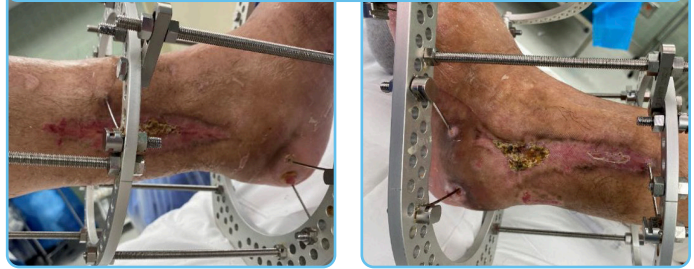
Ten weeks post op: medial wound with epithelial tissue at edges



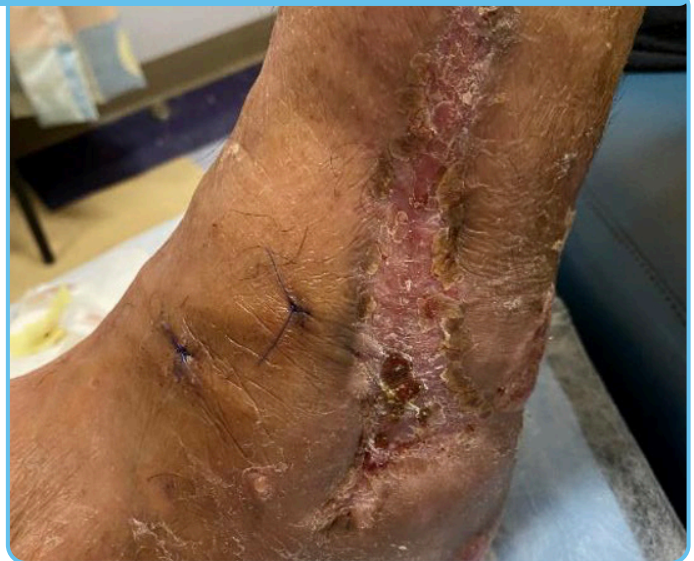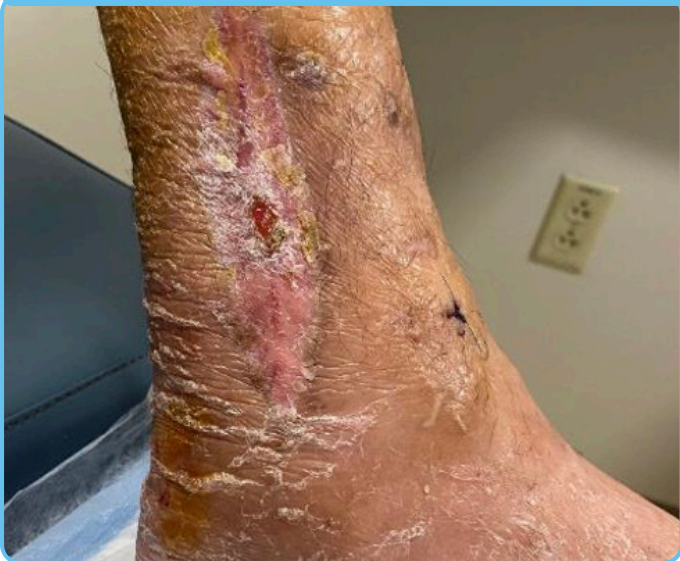Twelve weeks post op: wounds about closed



Thirteen weeks post op: medial wound completely closed



Fourteen weeks post op: 1st visit after frame removal



Outcome

- 13 weeks to complete closure with one application of STRAVIX PL Tissue for lateral and medial wounds

Tissue source	Product description	Part #
Lyopreserved umbilical tissue (stored at room temperature)	STRAVIX PL ^o 2 cm x 2 cm (4 cm ²)	PS61022
	STRAVIX PL 2 cm x 4 cm (8 cm ²)	PS61024
	STRAVIX PL 3 cm x 6 cm (18 cm ²)	PS61036
Cryopreserved umbilical tissue (stored between -75°C & -85°C)	STRAVIX Meshed 3 x 6 cm (18 cm ² **)	PS60036
	STRAVIX ^o 2 x 2 cm (4 cm ²)	PS60006
	STRAVIX 2 cm x 4 cm (8 cm ²)	PS60005
	STRAVIX 3 cm x 6 cm (18 cm ²)	PS60008

Improve outcomes faster, conveniently, without adding significant costs

STRAVIX PL and STRAVIX Meshed Tissues give you a step up

Visit stravixpl.com to learn more and see clinical cases and studies using STRAVIX PL and STRAVIX Tissues



stravixpl.com

Please see the Instructions for Use for indications, contraindications, warnings, precautions and other important information.

References: **1.** McGinness K, Kurtz Phelan DH. Use of viable cryopreserved umbilical tissue for soft tissue defects in patients with gas gangrene: A case series. *Wounds*. 2018; 30(4): 90-95. **2.** Fincke BG, Miller DR, Turpin R. A classification of diabetic foot infections using ICD-9-CM codes: Application to a large computerized medical database. *BMC Health Serv Res*. 2010; 10: 192. **3.** Dhall S, Coksaygan T, Hoffman T, et al. Viable cryopreserved umbilical tissue (vCUT) reduces post-operative adhesions in a rabbit abdominal adhesion model. *Bioact Mater*. 2018; 4(1): 97-106. **4.** Data on file at Osiris Therapeutics, Inc. **5.** Brandeisky J, Kurtz Phelan DH. Clinical outcome of Achilles tendon repair using viable intact cryopreserved umbilical tissue versus standard of care. *Wounds*. 2017; 29(11): E111-E114. **6.** Sundblad KW, Tassis EK. A quality improvement pilot assessment of the safety and associated outcomes of a viable cryopreserved umbilical tissue allograft as an adjunct surgical wrap in peroneus brevis tendon repair. *Medicine (Baltimore)*. 2018; 97(51): e13662.

©2023 Smith+Nephew, Inc. Osiris, STRAVIX and STRAVIX PL are trademarks of Osiris Therapeutics, Inc., a wholly owned direct subsidiary of Smith+Nephew Consolidated, Inc.

Advanced Wound Management Smith+Nephew, Inc. Fort Worth, TX 76109 USA
STRAVIX PL and STRAVIX Customer Care : T 888-674-9551 F 443-283-4419 | www.smith-nephew.com | www.stravixpl.com | STPE68-30032-1022